

We are IntechOpen, the world's leading publisher of Open Access books Built by scientists, for scientists

7,300

Open access books available

192,000

International authors and editors

210M

Downloads

Our authors are among the

154

Countries delivered to

TOP 1%

most cited scientists

14%

Contributors from top 500 universities



WEB OF SCIENCE™

Selection of our books indexed in the Book Citation Index
in Web of Science™ Core Collection (BKCI)

Interested in publishing with us?
Contact book.department@intechopen.com

Numbers displayed above are based on latest data collected.
For more information visit www.intechopen.com



Measurement of Anterior Chamber Angle with Optical Coherence Tomography

deOrta-Arellano F, Muñoz-Rodríguez P and Salinas-Gallegos JL
Diagnóstico Visual de Guadalajara
México

1. Introduction

Evaluation of the width of the anterior chamber angle and its inlet during the ophthalmic examination is essential in determining the susceptibility of the angle to closure (Kalev-Landoy et al 2007, Leung et al 2007, Leung et al 2008, Radhakrishnan et al 2005).

There are factors that have been recognized as affecting the anterior chamber angle width include age, race/ethnicity, iris color, eye dominance, corneal curvature and refraction, and illumination open or narrow angles may become closed in dark lighting conditions, which can lead to the diagnosis of angle-closure glaucoma being missed (Liu L 2008).

Since the clinical introduction of the slitlamp into ophthalmology by Vogt, the dimensions of the anterior segment of the eye have usually been estimated by slit-lamp-supported biomicroscopy of the eye (Xu L 2008).

Although gonioscopy is the gold standard for anterior chamber angle assessment (Baikoff G 2004, Kalev-Landoy et al 2007, Leung et al 2007, Radhakrishnan et al 2005), its inevitable need for minimal illumination to visualize the angle, the uncertainty of the change in angle configuration when a goniolens is in direct contact on the cornea, and the dependence on individual skill and experience for interpretation of the angle configuration, serve to limit its role in providing precise angle assessment. Reliable measurement of the anterior chamber angle was not possible until ultrasound biomicroscopy (UBM) became available (Kalev-Landoy et al 2007, Leung et al 2007). With UBM, detailed spatial relationships of the anterior chamber angle iridocorneoscleral junction can be visualized and quantified.

1.1 UBM and Anterior Segment-Optical Coherence Tomography (AS-OCT)

Optical coherence tomography has several advantages over the other techniques for objective assessment of the anterior chamber angle (Dada et al 2007).

UBM is a close contact immersion technique (Kalev-Landoy et al 2007, Leung et al 2007, Radhakrishnan et al 2005), There is a risk of infection or corneal abrasion due to the contact nature of the examination (Dada et al 2007, Radhakrishnan et al 2005). Inadvertent corneal indentation can cause artifactitious widening of the angle (Baikoff G 2004, Dada et al 2007, Leung et al 2007). By the time the image is captured, it may be difficult to judge the exact globe position and the precise clock-hour location at which the scan was aligned (Leung et al 2007). Ultrasound biomicroscopy is performed with the patient supine, positioning that theoretically causes the iris diaphragm to fall back. This deepens the anterior chamber and opens the angle (Dada et al 2007).

In UBM, there is no fixed reference point and the angle region measured is located subjectively as nasal, temporal, superior, inferior, and so forth, not in exact degrees of an arc. With UBM, only 1 quadrant can be imaged at a time. With AS-OCT, 4 quadrants can be scanned at once. The UBM procedure is more time consuming and requires a highly skilled operator to obtain high-quality precision images (Dada et al 2007, Radhakrishnan et al 2005). As a result, intra- and interobserver reproducibilities for angle measurements have been generally poor (Leung et al 2007).

Anterior Segment Optical Coherence Tomography (AS-OCT) is a non-contact, non-invasive light-based imaging modality of diagnostic technique (Dacosta et al 2008 Spectral Domain, Dacosta et al 2008 Indian J Ophthalmol, Dada, T et al. 2008, Leung et al 2007, Leung et al 2008, Sakata LM, Sunita et al) that provides image resolution higher than that of UBM (axial resolution of 18 μm in Visante OCT versus 50 μm in UBM) of the anterior segment in cross section (Dacosta et al 2008 Spectral Domain, Dada, T et al. 2008, Leung et al 2007, Leung et al 2008, Sunita et al) in vivo. Fig. 1 (Boyd S et al). Furthermore the use of wide-field scanning optics (16 mm) and deep axial scan range (8 mm) permit the AS-OCT to image the entire anterior chamber in a single frame. After acquisition, the scanned images are processed by a customized "dewarping" software, which compensates for the index of refraction transition at the air-tear interface and the different group indices in air, cornea, and aqueous to correct the images physical dimensions (Sakata LM). It allows for an objective assessment of the anterior chamber (AC) angle and is easy to use after minimal training. These characteristics compare favorably to the current gold standard, gonioscopy, which requires highly trained personnel, is subjective, and involves placing a lens on the eye of the patient (Sunita et al).

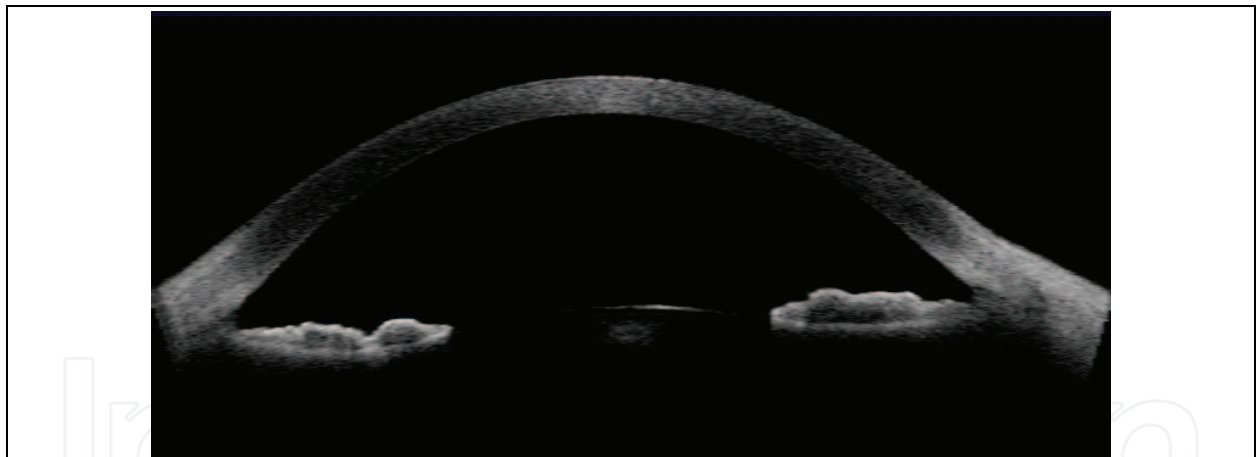


Fig. 1. OCT image of the anterior chamber

The working principle of OCT is similar to ultrasound (Dacosta et al 2008 Spectral Domain, Leung et al 2008, Dada et al 2007), which uses echoes to locate structures within the body. The speed of light being almost a million times faster than sound allows measurement of structures with a resolution of ≤ 10 microns as compared to 100 microns scale for ultrasound. (Dacosta et al 2008 Spectral Domain). OCT demonstrated excellent interobserver and intersession reproducibility for AC depth measurements and good to excellent interobserver and intersession reproducibility for angle parameters in the nasal and temporal quadrants. (Sunita et al).

With OCT, the user can view multiple cross-sectional image of the anterior chamber angle. As it use an infrared light, pupil doesn't close by providing a more natural image of angle structures without modifying their anatomy. Measurement software can be used to calculate

the depth of the angle in degrees (Boyd S et al), or in mm (Angle Opening Distance, AOD) and mm² (Trabecular Iris Space Area, TISA) Fig 2.

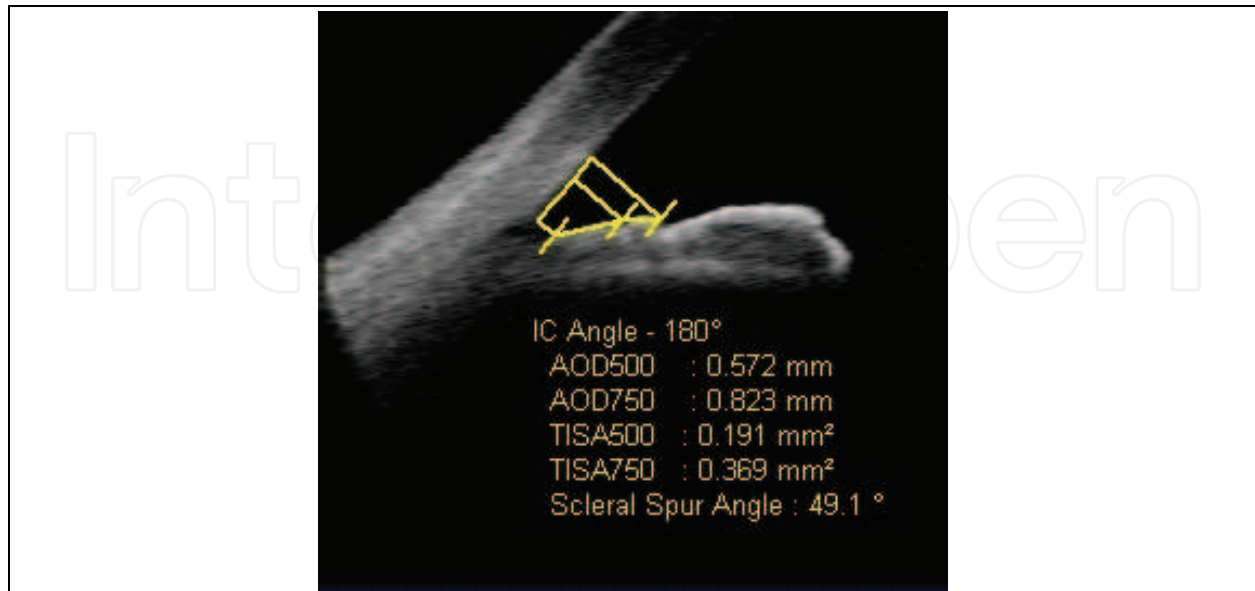


Fig. 2. Measurement of quantitative angle parameters using Visante OCT. Illustrated are angle opening distance (AOD), trabecular-iris space area (TISA) 500 or 750 μ m from scleral spur.

Age and refractive error were found to be associated with anterior chamber angle measurement; one may argue that some adjustment would be required since the objective of the study was to provide population normative data (Xu L 2008).

2. Optical coherence tomography

Anterior segment optical coherence tomography is described as an attractive technique for optical biopsy because it can image tissue microstructure in situ, yielding micron-scale image resolution without the need to excise a specimen and process tissue processing. Optical coherence tomography has several advantages over the other techniques for objective assessment of the anterior chamber angle. Anterior segment optical coherence tomography can perform measurements without a coupling medium as it uses light energy (Dada et al 2007).

Optical Coherence tomography is based on the principle of Michelson interferometry. (Dacosta et al 2008 Spectral Domain, Dada T et al 2008). Broad bandwidth infrared light (of 1310 nm) first reported by Radhakrishnan et al using a system developed by Izatt's group Dada et al 2007 generated by using a superluminescent diode projected on the tissue (Boyd S et al, Dacosta et al, Leung et al 2007, Leung et al 2008, Sunita et al). 1310 nm wavelength of light is strongly absorbed by water in the ocular media and, therefore, only 10% of the light incident on the cornea reaches the retina (Radhakrishnan et al). The light is then broken into combination of reflected light from the sample arm and light from the reference arm gives rise to an interference pattern. By scanning the mirror in the reference arm, a reflectivity profile of the sample can be obtained. This reflectivity profile, called an A-scan contains information about the spatial dimension and location of structures within the item of interest. A cross-sectional tomography (B-Scan) may be achieved by laterally combining a series of these axial depth scan (A-scan) (Dacosta et al 2008 Spectral Domain). Images generated are easy to interpret (Dacosta et al 2008 Spectral Domain, Dada T et al 2008).

With standard software, the lateral resolution of AS-OCT is 60 μm and the axial resolution is 18 μm compared with 50 μm and 25 μm , respectively, with UBM. With high-resolution corneal software, axial resolution of AS-OCT can reach 8 μm . With the Visante AS-OCT, anterior segment scans up to 6.0 mm deep and 16.0 mm wide can be performed (data by Carl Zeiss Meditec). Important landmarks such as the scleral spur are more distinct in AS OCT images. With AS-OCT, one can also examine the posterior capsule of the lens, which is not possible with UBM (Dada et al 2007).

The AS-OCT image represents the differential backscattering contrast between different tissue types on a micron scale. It is a gray scale or false color 2-dimensional representation of backscattered light intensity in a cross-sectional plane (Dada et al 2007). It gives almost same details as that of UBM, with an additional advantage of being non-contact. This provides a detailed view of cornea, angle and angle recess, sclera and scleral spur; iris and its root, ciliary body and ciliary body band and the limbus Fig 3. Sclera and the scleral spur are seen as highly reflective structures and ciliary body is seen as a hyporeflective structure. It allows a direct measure the anterior chamber angle.

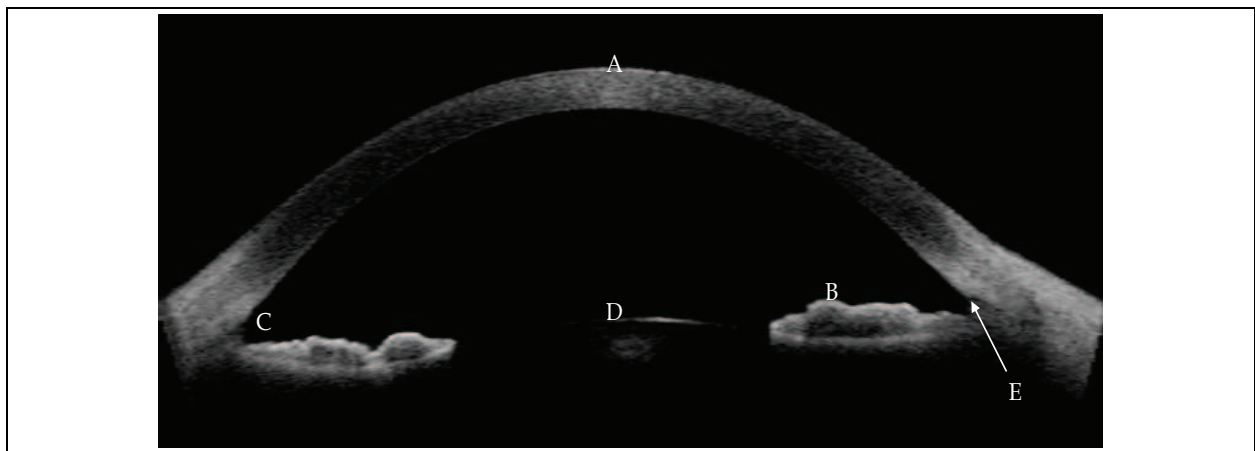


Fig. 3. Anterior segment OCT image. Illustrated (A) cornea, (B) iris, (C) anterior chamber angle, (D) lens and (E) scleral spur.

The imaging information provided by anterior segment OCT equates well with the UBM findings, biggest advantage of OCT over UBM is that the former being non-invasive and non contact (Dada, T et al 2008, Leung et al 2007, Leung et al 2008) it can be used in the imaging of the angle in immediate postoperative period and also in eyes with anterior segment trauma. Nozaki et al reported the anterior segment OCT findings after non-penetrating deep sclerectomy. They showed that OCT is capable of providing information regarding the status of bleb, trabeculo-Descemet's membrane, and bleb height (Dada, T et al).

Reliable documentation of the angle dimensions is also dependent on precise localization of the scleral spur (Leung et al 2008). The scleral spur in anterior segment imaging is marked by a prominent inner extension of the sclera (its thickest part) and represents an anatomical landmark for the trabecular meshwork, which is located approximately 250 to 500 μm anterior to the scleral spur along the angle wall (Sakata LM).

Previous UBM studies failed to attain repeatable measurements of the angle. The study by Urbak et al., who used the same UBM images for measurement, the intraobserver coefficient of variation for AOD was up to 16.97%, with significant differences ($P < 0.001$) found between observers. Measurement reproducibility was affected by subjective interpretation of visualized anatomic landmarks, which is directly related to image resolution (Leung et al 2008).

2.1 Image acquisition

In a retrospective observational study, the anterior chamber angle was measured using anterior segment images of OCT in 130 eyes of 72 patients. All subjects underwent an ophthalmic examination including visual acuity, slit-lamp biomicroscopy, autokeratorefractometry with KR-8000 (Topcon).

Exclusion criteria in our group of patients were history of glaucoma, trauma, ocular disease, previous ocular surgery including laser trabeculoplasty, laser iridotomy, laser photocoagulation, pterygium surgery, refractive surgery.

Scans were acquired with internal fixation target under dark conditions with angle protocol, which gives enhanced anterior segment single scan and global pachymetry map. This analysis detects corneal tissue, iris, lens anterior surface, anterior chamber. Angle measurements can be determined by manual detection of scleral spur. The inbuilt algorithm measures angle in both side of anterior chamber giving AOD 500, AOD 750, TISA 500, TISA 750. To perform AS OCT imaging in a non-accommodated state, the subjects refractive correction was used to adjust the internal fixation target for the patients distance correction. All scans were taken by a single examiner. Scans were centered on the pupil and taken along the horizontal meridian (nasal - temporal angles at 0 to 180 degrees).

We analyzed the nasal and temporal angles, because they are more accessible than the superior and inferior angles. Lid manipulation is always necessary for superior and inferior angle imaging and may lead to inadvertent change in angle configuration.

3. Results

3.1 Measurement obtained of anterior chamber angle in myopic eyes

Measures were obtained from 52 eyes of 26 patients with mean of myopic refraction of -2.23 D (range - 0.75 to - 3.75) Fig. 4 and cylinder less than - 2.75 D obtained from Auto-keratorefractometer KR-8000 (Topcon): 11 men, 15 women. Mean of age 28 years (range 18 to 67 years old). The mean of AOD 500 measured was 0.636 mm (SD 0.202), AOD 750: 0.912 mm (SD 0.274), TISA 500 0.217 mm² (SD 0.071), TISA 750: 0.412 mm² (SD 0.131).

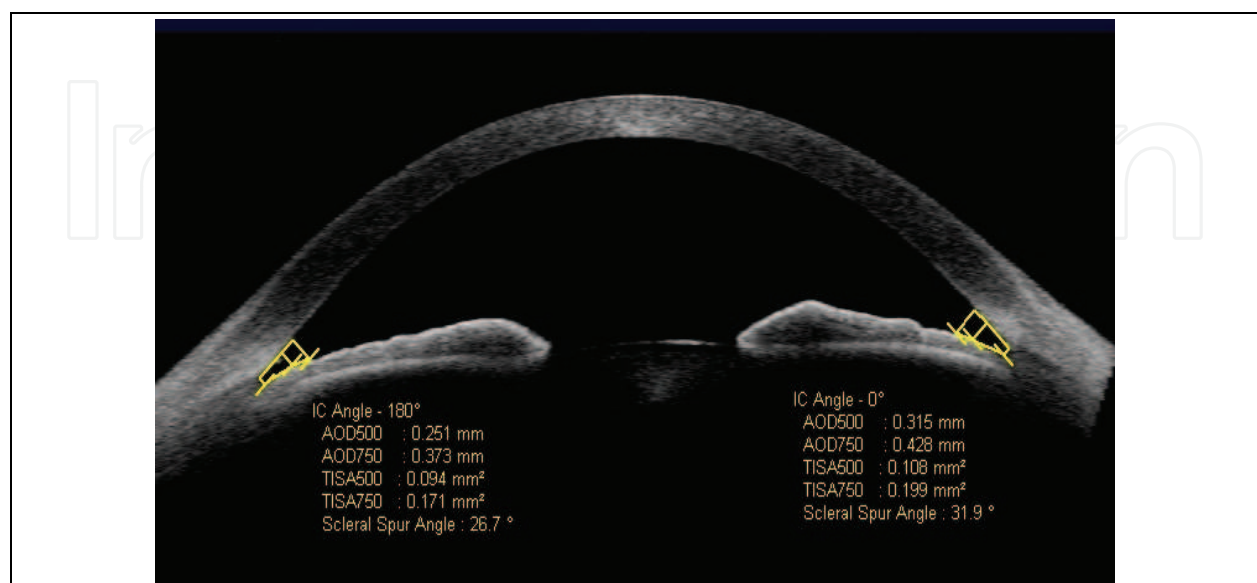

Fig. 4. Measurement of anterior chamber angle in myopic patient (- 2.50 = - 0.50 x 20°)

3.2 Measurement obtained of anterior chamber angle in hypermetropic eyes

Measures were obtained from 43 eyes of 24 patients with mean of refraction + 1.60 D (+ 0.25 to + 9.25 D): 10 men, 14 women. Mean of age 45 years (range 21 to 75 years). The mean of AOD 500 measured was 0.372 mm (SD 0.167), AOD 750: 0.528 mm (SD 0.210), TISA 500 0.131 mm² (SD 0.062), TISA 750: 0.243 mm² (SD 0.105).

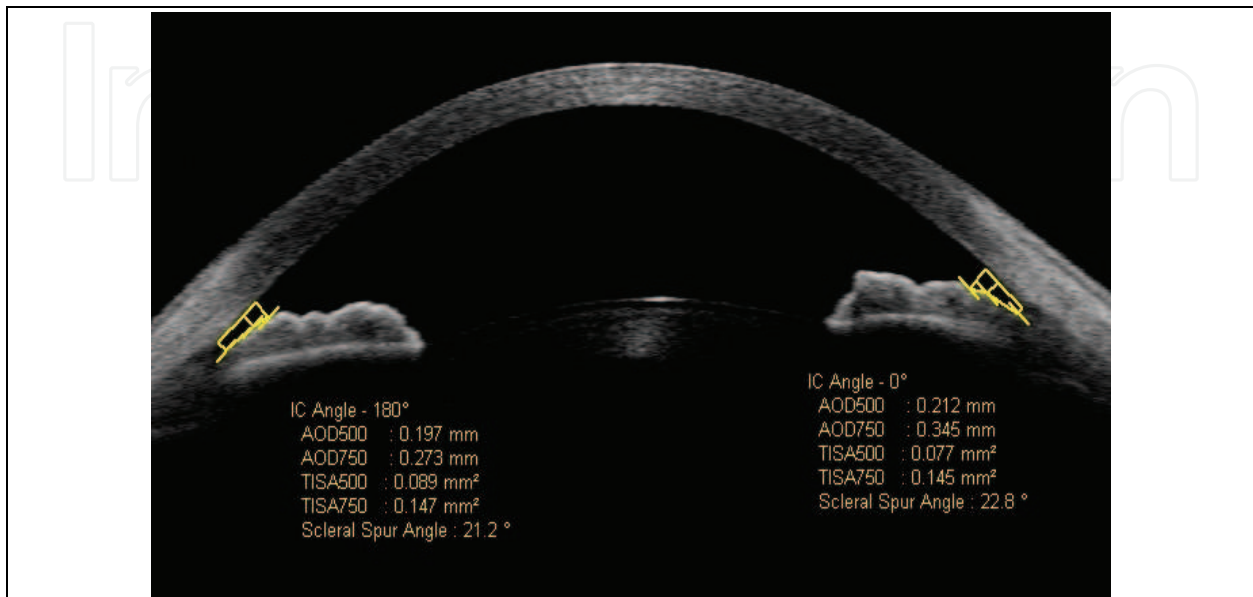


Fig. 5. Measurement of anterior chamber angle in hypermetropic patient (+ 6.00 = - 1.25 x 130°)

3.3 Measurement obtained of anterior chamber angle in high myopic eyes

Measures were obtained from 20 eyes of 11 patients with mean of refraction of - 6.61 (- 4.00 to - 10.50 D) cylinder less than - 2.75 D: 6 men, 5 women. Aged 26 years old (from 18 to 49 years). The AOD 500 measured was 0.845 mm (SD 0.398), AOD 750: 1.181 mm (SD 0.510) , TISA 500 0.286 mm² (SD 0.134) , TISA 750: 0.555 mm² (SD 0.282).

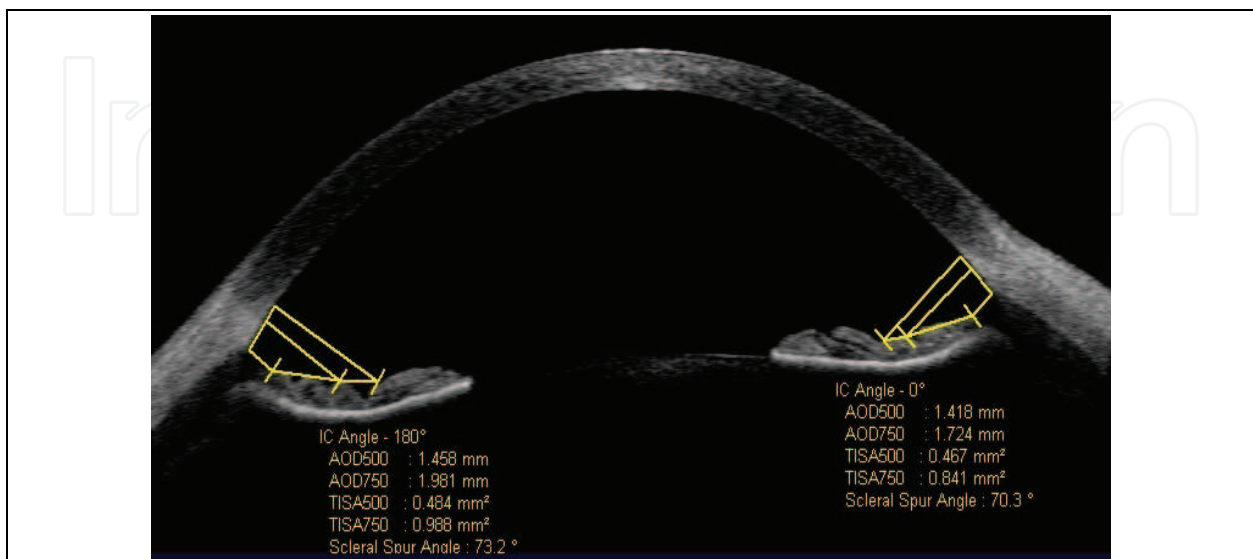


Fig. 6. Measurement of anterior chamber angle in high myopia patient (- 9.00 = - 0.50 x 100°).

3.4 Measurement obtained of anterior chamber angle in high astigmatic eyes

Measures were obtained from 15 eyes of 11 patients: 5 men, 6 women. Aged 25 years (from 17 to 33 years) with cylinder refraction - 5.32 (- 4.00 to - 7.00), spherical refraction - 2.23 (- 0.25 to -3.75). The AOD 500 measured was 0.660 mm (SD 0.270), AOD 750: 0.910 mm (SD 0.357), TISA 500 0.220 mm² (SD 0.096), TISA 750: 0.415 mm² (SD 0.172).

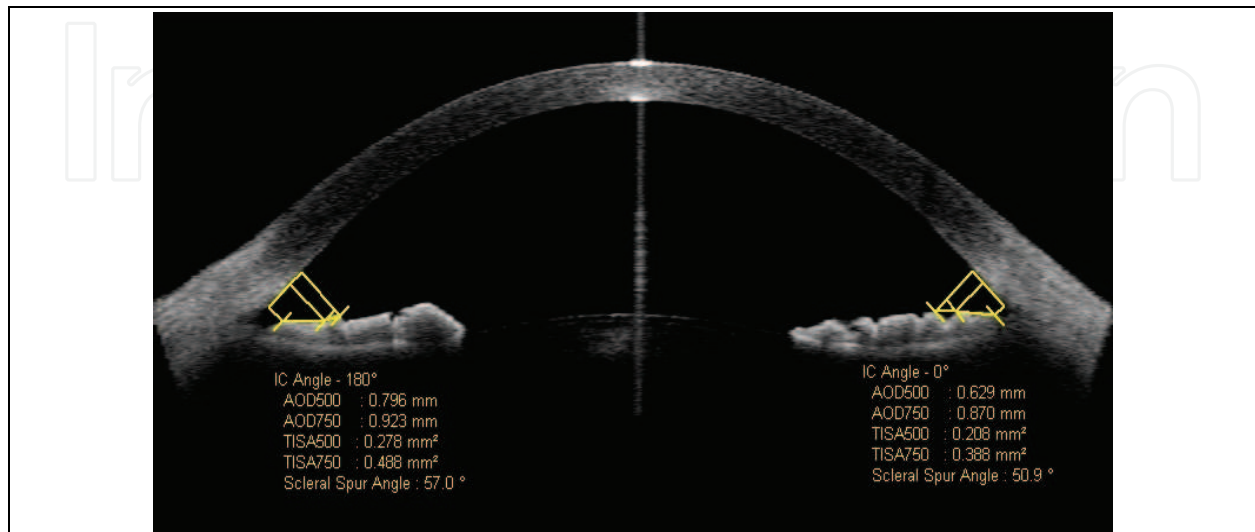


Fig. 7. Measurement of anterior chamber angle in astigmatic patient (+ 0.25 = - 5.00 x 180°)

	AOD 500 mm	AOD 750 mm	TISA 500 mm ²	TISA 750 mm ²
Hypermetropia	0.372	0.528	0.131	0.243
Myopia	0.636	0.912	0.217	0.412
High Astigmatism	0.660	0.910	0.220	0.415
High Myopia	0.845	1.181	0.286	0.555

Table 1. Difference of the media of anterior chamber angle measures between groups. AOD (Angle open distance), TISA (trabecular iris space area).


4. Conclusion

On routine gonioscopy, the angle structures may not be identified in eyes with a steep iris configuration and a narrow angle. A steep approach to the angle makes examination difficult in such cases. OCT Visante is one technique for objective estimation of angle measures even in difficult eyes. It is important to make angular measurements in greater groups of population to determine the normal variation of the angular values of AOD and TISA to compare it with glaucoma angles and to determine the angular values of risk for angular closing.

5. References

Baikoff G, Lutun E, Ferraz C, Wei J (2004) Static and dynamic of the Anterior Segment with Optical Coherence Tomography. *J Cataract Refract Surg* (Sept 2004) Vol. 30 No.9 pp. 1843-50.

- Boyd S., Brancato R., Straatsma B. (2009) *Tomografía de Coherencia Óptica. Atlas y texto*. Jaypee-Highlights. ISBN 978-9962-678-05-2, Panamá, Panamá.
- Dacosta S, Fernandes G, Rajendran B, Janakiraman P (2008) Assessment of anterior segment parameters under photopic and scotopic conditions in Indian eyes using anterior segment optical coherence tomography *Indian J Ophthalmol* (February 2008) ; Vol 56 No. 1. pp. 17-22.
- Dacosta S., Rajendran B., Janakiraman (2008). *Spectral Domain OCT*. 1a ed. Mc Graw Hill, ISBN 978-81-8448-311-6. New Delhi, India.
- Dada T, Sihota R, Gadia R, Aggarwal A, Mandal S, Gupta V (2007) Comparison of anterior segment optical coherence tomography and ultrasound biomicroscopy for assessment of the anterior segment *J Cataract Refract Surg* (May 2007); Vol. 33 pp 837-840.
- Dada,T., Sony P.,Sihota R. (2008). Clinical Utility of OCT in Glaucoma, In: *Techniques in Glaucoma Diagnosis and Treatment* , Garg, A., Mortensen JN., Marchini G., Mehta KR., Khalil AK., Melamed S., Bovet JJ., Carassa R., Dada T., Mehta C. (116-127). Mc Graw Hill, ISBN-13: 978-0-07-160195-5, New Delhi, India.
- Kalev-Landoy M, Day AC, Cordeiro MF & Migdal C (2007). Optical coherence tomography in anterior segment imaging. *Acta Ophthalmol Scand*. Vol. 85, No.4 (June 2007) pp 427-430.
- Leung CK, Cheung CY, Li H, Dorairaj S, Yiu CK, Wong AL, Liebmann J, Ritch R, Weinreb R & Lam DS (2007) Dynamic Analysis of Dark-Light Changes of the Anterior Chamber Angle with Anterior Segment OCT *Invest Ophthalmol Vis Sci.*, Vol. 48, No. 9 (September 2007) pp. 4116-4122
- Leung CK, Li H, Weinreb RN, Liu J, Cheung CY, Lai RY, Pang CP & Lam DS (2008) Anterior Chamber Angle Measurement with Anterior Segment Optical Coherence Tomography: A Comparison between Slit Lamp OCT and Visante OCT *Invest Ophthalmol Vis Sci* Vol. 49 , No. 8, (August 2008) pp. 3469-74.
- Liu L (2008) Anatomical Changes of the Anterior Chamber Angle With Anterior-Segment Optical Coherence Tomography *Arch Ophthalmol*. (Dec 2008) Vol. 126 No. 12. pp.1682-1686
- Radhakrishnan S, Goldsmith J, Huang D, Westphal V, Dueker DK, Rollins AM, Izatt JA, Smith SD (2005) Comparison of optical coherence tomography and ultrasound biomicroscopy for detection of narrow anterior chamber angles *Arch Ophthalmol* (Aug 2005) Vol 123 No. 8. pp. 1053-9.
- Sakata LM, Lavanya R, Friedman DS, Aung HT, Seah SK, Foster PJ & Aung T. (2008). Assessment of the scleral spur in anterior segment optical coherence tomography images. *Arch Ophthalmol*. Vol. 126 No. 2. pp 181-5.
- Sunita Radhakrishnan, Jovina See, Scott D. Smith, Winifred P. Nolan, Zheng Ce, David S. Friedman, David Huang, Yan Li, Tin Aung, & Paul T. K. Chew (2007). Reproducibility of Anterior Chamber Angle Measurements Obtained with Anterior Segment Optical Coherence Tomography, *Invest Ophthalmol Vis Sci*. Vol.48, No. 8. (August 2007): pp. 3683-3688.
- Xu L, Cao WF, Wang YX, Chen CX & Jonas JB (2008). Anterior Chamber Depth and Chamber Angle and Their Associations with Ocular and General Parameters: The Beijing Eye Study. *Am J Ophthalmol*. Vol. 145 no. 5 (May 2008) pp. 929-36



The Mystery of Glaucoma

Edited by Dr. Tomas Kubena

ISBN 978-953-307-567-9

Hard cover, 352 pages

Publisher InTech

Published online 06, September, 2011

Published in print edition September, 2011

Since long ago scientists have been trying hard to show up the core of glaucoma. To its understanding we needed to penetrate gradually to its molecular level. The newest pieces of knowledge about the molecular biology of glaucoma are presented in the first section. The second section deals with the clinical problems of glaucoma. Ophthalmologists and other medical staff may find here more important understandings for doing their work. What would our investigation be for, if not owing to the people's benefit? The third section is full of new perspectives on glaucoma. After all, everybody believes and relies – more or less – on bits of hopes of a better future. Just let us engage in the mystery of glaucoma, to learn how to cure it even to prevent suffering from it. Each information in this book is an item of great importance as a precious stone behind which genuine, through and honest piece of work should be observed.

How to reference

In order to correctly reference this scholarly work, feel free to copy and paste the following:

De Orta-Arellano F, Muñoz-Rodriguez P and Salinas-Gallegos JL (2011). Measurement of Anterior Chamber Angle with Optical Coherence Tomography, The Mystery of Glaucoma, Dr. Tomas Kubena (Ed.), ISBN: 978-953-307-567-9, InTech, Available from: <http://www.intechopen.com/books/the-mystery-of-glaucoma/measurement-of-anterior-chamber-angle-with-optical-coherence-tomography>

INTECH
open science | open minds

InTech Europe

University Campus STeP Ri
Slavka Krautzeka 83/A
51000 Rijeka, Croatia
Phone: +385 (51) 770 447
Fax: +385 (51) 686 166
www.intechopen.com

InTech China

Unit 405, Office Block, Hotel Equatorial Shanghai
No.65, Yan An Road (West), Shanghai, 200040, China
中国上海市延安西路65号上海国际贵都大饭店办公楼405单元
Phone: +86-21-62489820
Fax: +86-21-62489821

© 2011 The Author(s). Licensee IntechOpen. This chapter is distributed under the terms of the [Creative Commons Attribution-NonCommercial-ShareAlike-3.0 License](#), which permits use, distribution and reproduction for non-commercial purposes, provided the original is properly cited and derivative works building on this content are distributed under the same license.

IntechOpen

IntechOpen